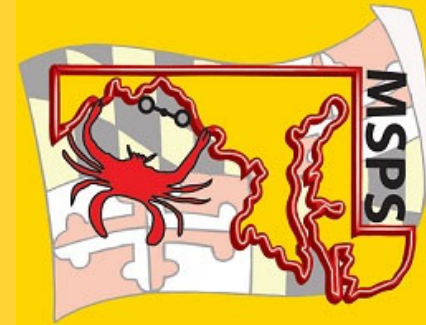

# Welcome to the 12th Annual MAVES

3 May 2020



Thank YOU, 2020 vendors, for your support!!

*During the breaks, please visit our supporting vendors in their breakout room through the CHAT function and be entered into a raffle for Amazon gift cards!*

**BOEHRINGER**®

**PLATINUM SPONSORS**

Caring for Lives through Innovation, Quality and Service

**LivaNova**  
Health innovation that matters

**Spectrum Medical**

**TERUMO**

**inVosurg** **SILVER SPONSORS** **Abbott**

# Our COVID-19 ECMO Experience

Hasratt Mohamed, CCP | Gilbert Garcia, CCP | Skye Brown, CCP



Tavares, Florida

The image shows the exterior of the Florida Hospital Waterman Emergency Department. The building is a modern, multi-story structure with a curved facade and large glass windows. In the foreground, there is a paved area with a yellow curb. A large, white, tent-like canopy structure is supported by several white poles. A red sign with white text is visible, reading "FLORIDA HOSPITAL Waterman EMERGENCY" and providing directions for "Emergency Visitor Parking" and "Main Entrance".

# Challenges

- ▶ Normal Vs COVID-19
- ▶ COVID-19 APPROACH
- ▶ Precautions
- ▶ Thinking outside the Box



# Normal Vs COVID-19

## Normal ECMO

- ▶ Effortless
- ▶ Routine Maintenance

## COVID-19 ECMO:

- ▶ Staffing, location, No. ECMOs
- ▶ CCP/RN out of room
- ▶ Delayed interventions
- ▶ PPE used all day
- ▶ Alarm fatigue
- ▶ No Hazard pay
- ▶ Increased stress level/anxiety for family and Staff

## COVID-19 VV ECMO Patients N= 6

- ▶ 3 Expired
- ▶ 1 Off VV ECMO  
Ding Well (oldest)
- ▶ 2 Still on

### Demographics:

- ▶ 2 female Expired
- ▶ 1 Male expired
- ▶ Age range 41-72  
year of age

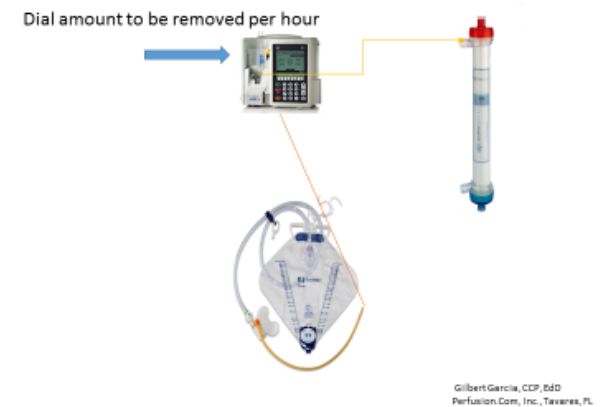
# Behavior Of COVID19 Patients on VV ECMO

- ▶ ARDS, Honeycomb Lungs
  - ▶ High PEEP, Airway Pressure
  - ▶ Severe Hypoxemia
  - ▶ Hyper Coagulable
  - ▶ Prone to Peripheral, Cerebral and Pulmonary Tromboembolism
  - ▶ Cardiac muscle edema
- ▶ Current Treatment:
  - ▶ Hydroxychloroquine (Plaquenil)\*
  - ▶ Azithromycin (Z-Pak)\*
  - ▶ Convalescent Plasma (new)
  - ▶ Cytosorb (new)\*
  - ▶ Remdesivir (new)
- ▶ No one knows enough about this disease, thus no definitive treatment as yet.

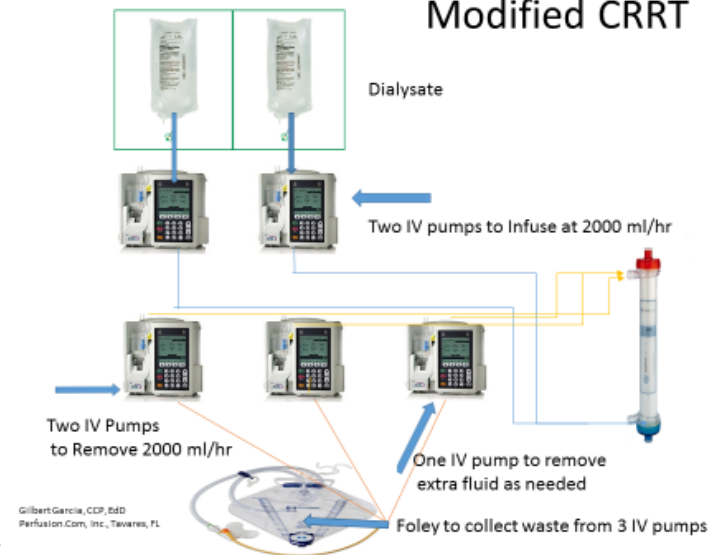
# Our Approach

- ▶ All Cannulations in CVOR
- ▶ Daily Bronchoscopies
- ▶ ASAP Tracheostomies
- ▶ Daily X-Rays
- ▶ KeepTemp: 36C
- ▶ Hemoconcentrator is Used
- ▶ Modified CRRT as Needed

## Precise Fluid Removal on ECMO



## Modified CRRT





# Anticoagulation/Rx

- ▶ 10,000 IU Heparin during Cannulation
- ▶ Angiomax Drip for the duration of VV ECMO
- ▶ No Steroids
- ▶ Sedation:  
Ketamine, Fentanyl, Morphine, Versed, Ativan
- ▶ Bicarb Drip

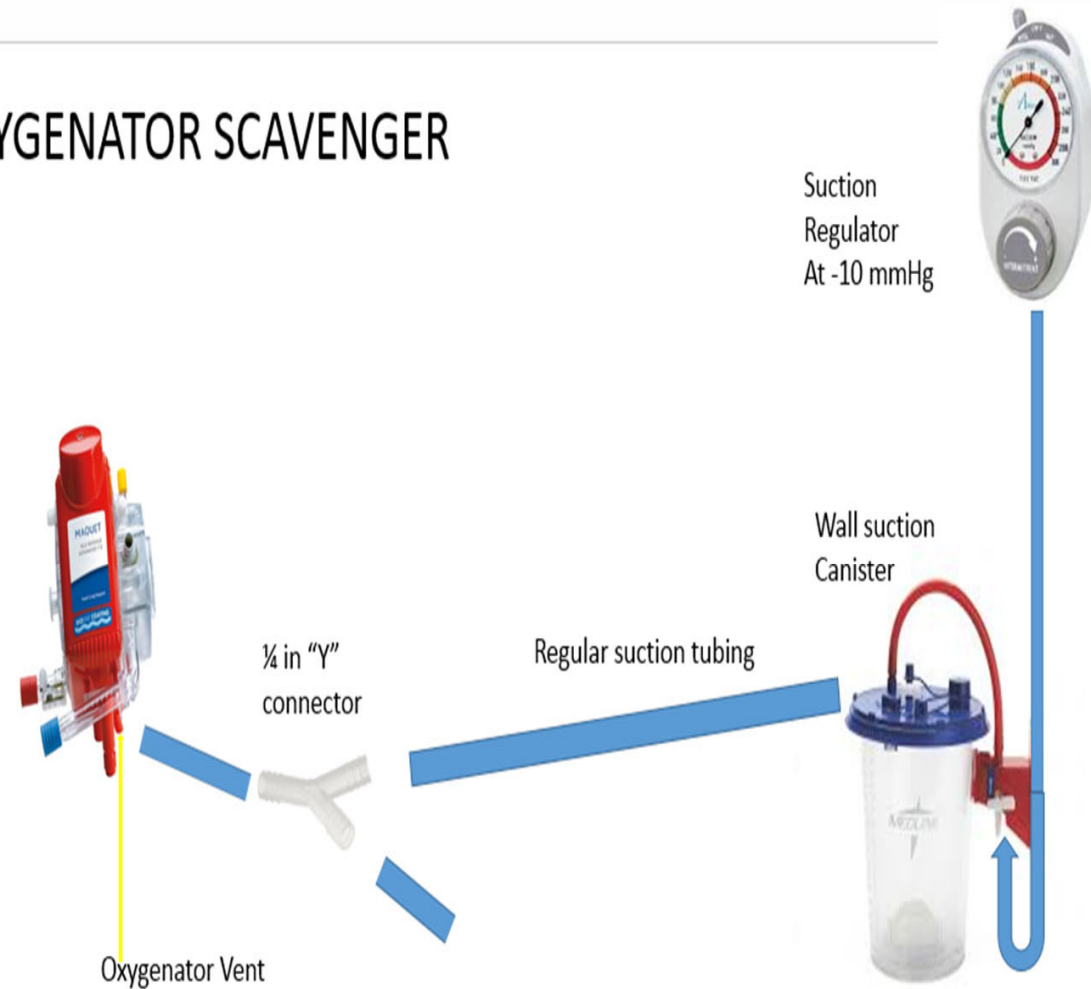
## Rest Ventilator setting:

- ▶ Minimal Peep (5 cmH<sub>2</sub>O)
- ▶ Low VT (usually 300ml)
- ▶ Low Peak Pressure (<30cmH<sub>2</sub>O)
- ▶ FiO<sub>2</sub> 30-40%
- ▶ Levo, Neo, Vasopressin PRN
- ▶ Strict I/O Management
- ▶ Albumen PRN



# Precautions

- ▶ Turn Ventilator OFF during Bronchoscopy
- ▶ HEPA Filter for the Exhalation tube of Ventilator
- ▶ Oxygenator Scavenger
- ▶ Remote view of Cardiohelp with Adaptation of Baby Monitor
- ▶ PPE

## OXYGENATOR SCAVENGER



# Remote View Of ECMO Console Vtech Owl

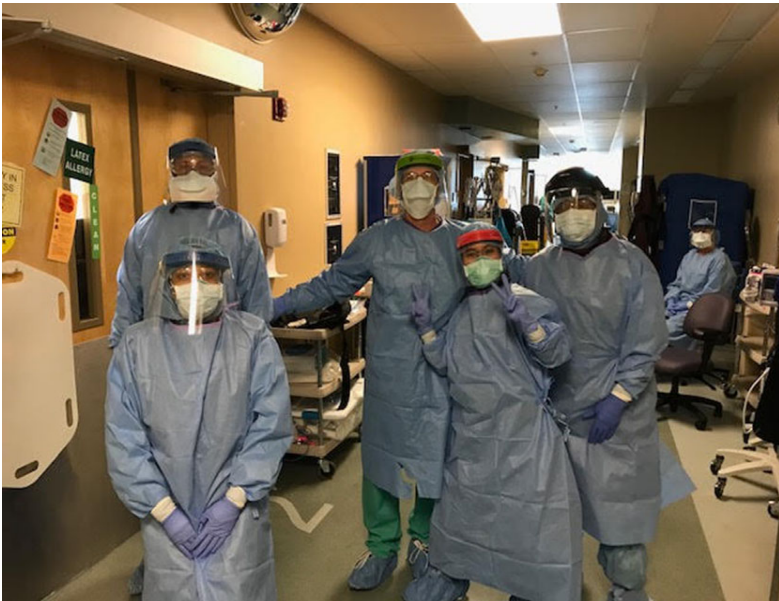

by Jodie Kollipinski, RN  
ECMO Specialist



# Thank You

DO



Don't

